

Asian Journal of Neurosurgery

AJNS

www.asianjns.org

Review Article

Trigeminal Neuralgia

Original Articles

Organized Chronic Subdural Hematomas Treated by Large Craniotomy with Extended Membranectomy as the Initial Treatment

Endoscopic Third Ventriculostomy in Normal Pressure Hydrocephalus and Symptomatic Long-standing Overt Ventriculomegaly

Formulation and Characterization of Nanomedicine (Solid Lipid Nanoparticle) Associate with the Extract of *Pterospermum acerifolium* for the Screening of Neurochemicals and Neuroendocrine Effects

Outcomes of Minimally Invasive Surgery Compared to Open Posterior Lumbar Instrumentation and Fusion

Intraoperative Anatomical and Hemodynamic Analysis of Intracerebral Arteriovenous Malformations by Semi-quantitative Color-coded Indocyanine Green Videoangiography

Case Reports

Pneumocephalus Presenting as Sudden Thunderclap Headache

Intradural Eosinophilic Granuloma Invading Skull: Case Report and Review of the Literature

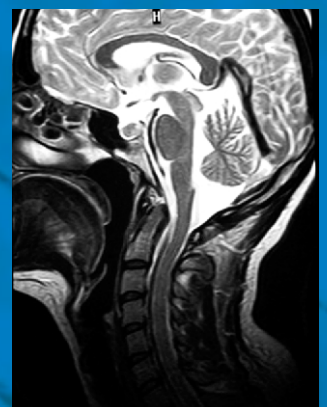
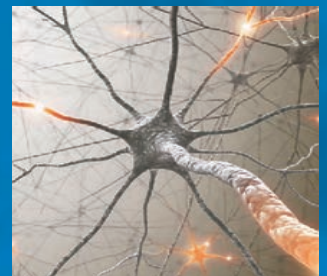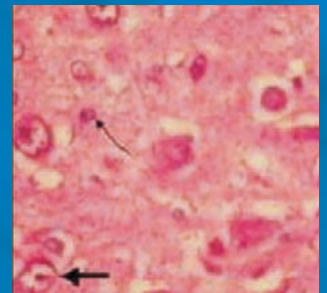
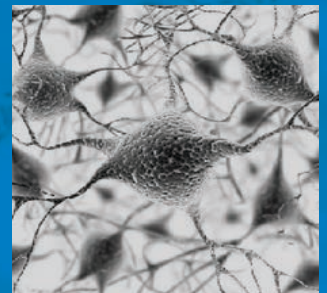
Unruptured Internal Carotid Artery Aneurysm Associated with Functional Pituitary Adenoma: A True Association

Lhermitte–Duclos Disease: A Rare Cause of Cerebellar Ataxia

Letters to Editor

Intracranial Hemorrhage in Dengue: Where Is It?

Carotid Endarterectomy: A Video Demonstration



Agenesis of the Internal Carotid Artery with Transcavernous Anastomosis Associated with Anterior Communicating Artery Aneurysms

Abstract

Agenesis of the internal carotid artery (ICA) is a rare congenital anomaly. Recently, several cases of ICA agenesis have been associated with cerebral aneurysms. We present the seventh case of ICA agenesis with transcavernous anastomosis associated with cerebral aneurysms. A 47-year-old man presented with transient numbness of his left hand. Magnetic resonance angiography indicated the presence of anterior communicating artery (ACoA) aneurysms. Digital subtraction angiography revealed two ACoA aneurysms, absence of the left ICA, and an anomalous collateral vessel connecting the cavernous portions of both internal carotid arteries, which was considered to be a transcavernous anastomosis. Head bone window computed tomography with contrast medium revealed the absence of the petrous carotid canal on the left suggesting the diagnosis of left ICA agenesis. The ACoA aneurysms were clipped successfully, and the postoperative course was uneventful.

Keywords: Agenesis, aneurysm, internal carotid artery, transcavernous anastomosis

Introduction

Agenesis, aplasia, and hypoplasia of the internal carotid artery (ICA) are extremely rare congenital anomalies, occurring in <0.01% of the population.^[1] These conditions are most commonly detected incidentally, and the clinical symptoms are rare. Agenesis is considered to represent a complete failure of the artery to develop in the absence of the carotid canal at the skull base.^[2,3] The most common source of collateral circulation in the case of ICA agenesis is via the circle of Willis.^[4] Usually in these cases, the basilar artery or the contralateral ICA supplies the middle cerebral artery (MCA) and anterior cerebral artery (ACA) on the side of the absent ICA.^[4] However, much less commonly, the collateral circulation is supplied by a transcavernous vessel connecting the ICAs.^[4-7] Recently, several cases of ICA agenesis have been associated with cerebral aneurysms.^[5-9] We describe an extremely rare case of unilateral ICA agenesis with transcavernous anastomosis associated with unruptured anterior communicating artery (ACoA) aneurysms.

Case Report

A 47-year-old man, with no significant medical history, presented with transient

This is an open access article distributed under the terms of the Creative Commons Attribution-NonCommercial-ShareAlike 3.0 License, which allows others to remix, tweak, and build upon the work non-commercially, as long as the author is credited and the new creations are licensed under the identical terms.

For reprints contact: reprints@medknow.com

numbness of his left hand. Magnetic resonance angiography indicated the presence of ACoA aneurysms, so he was admitted to our hospital for further examination. On admission, neurological examination revealed no abnormalities. Digital subtraction angiography revealed two ACoA aneurysms of approximately 5-mm and 3-mm diameter, absence of the left ICA, and an anomalous collateral vessel connecting the cavernous portions of both ICAs, which was considered to be a transcavernous anastomosis [Figure 1a-c]. The left ACA was supplied via the ACoA [Figure 1a-c]. Head bone window computed tomography with contrast medium revealed the absence of the petrous carotid canal on the left [Figure 1d] suggesting the diagnosis of left ICA agenesis. The ACoA aneurysms were clipped successfully via a frontal craniotomy and an interhemispheric approach [Figure 2], and the postoperative course was uneventful. He was discharged 10 days after surgery without neurological deficit.

Discussion

The incidence of intracranial aneurysm associated with agenesis or aplasia has been reported as 25–43%, which is much higher than that found in the general population of 2–4%.^[10] The

How to cite this article: Kumagai K, Takeuchi S, Otani N, Komiyama M, Mori K. Agenesis of the internal carotid artery with transcavernous anastomosis associated with anterior communicating artery aneurysms. *Asian J Neurosurg* 2017;12:801-3.

**Kosuke Kumagai,
Satoru Takeuchi,
Naoki Otani,
Masaki Komiyama¹,
Kentaro Mori**

*Department of Neurosurgery,
National Defense Medical
College, Saitama, ¹Department
of Neurosurgery, Osaka City
General Hospital, Osaka, Japan*

Address for correspondence:

*Dr. Satoru Takeuchi,
Department of Neurosurgery,
National
Defense Medical College, 3-2
Namiki, Tokorozawa,
Saitama 359-8513, Japan.
E-mail: s.takeuchi@room.ocn.
ne.jp*

Access this article online

Website: www.asianjns.org

DOI: 10.4103/1793-5482.181125

Quick Response Code:



high occurrence of aneurysm formation is most likely secondary to the altered hemodynamics of blood flow through the collateral channels supplying the involved vascular territories. Six pathways of collateral circulation have been described in association with absence of the ICA.^[4] Unilateral ICA agenesis can be divided into Type A, Type B, or Type D, and Type A is the most common.^[4] In Type A, unilateral absence of the ICA is associated with collateral circulation to the ipsilateral ACA through the patent ACoA, and the ipsilateral MCA from the posterior circulation through a hypertrophic posterior communicating artery. In Type B, the ipsilateral ACA and MCA are supplied through the patent ACoA. Type D represents unilateral agenesis of the cervical portions of the ICA with intercavernous communication to the ipsilateral carotid siphon from the contralateral, cavernous ICA. Therefore, our case belonged to Type D because the transcavernous (intercavernous) vessel connected both cavernous segments of the ICAs.

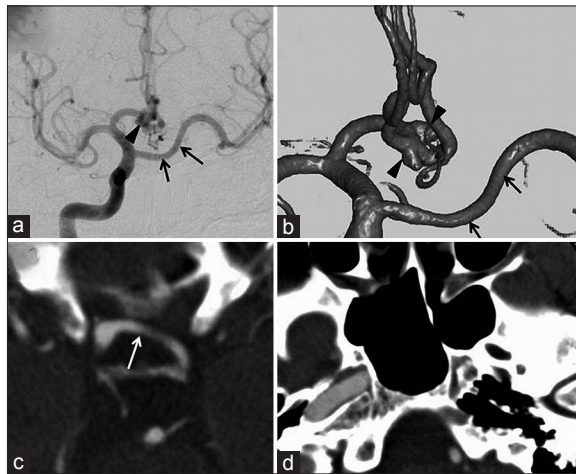


Figure 1: Right carotid angiogram (anteroposterior view) (a) three-dimensional digital subtraction angiogram. (b) Two anterior communicating artery aneurysms (arrowheads) of approximately 5-mm and 3-mm diameter, absence of the left internal carotid artery, and transcavernous anastomosis (arrows). Head enhanced computed tomography scan at the cavernous sinus. (c) Transcavernous anastomosis (arrow). Note that the left anterior cerebral artery is supplied via the anterior communicating artery. Head bone window axial computed tomography scan with contrast medium. (d) Absence of the petrous carotid canal on the left

Only seven cases of Type D agenesis associated with cerebral aneurysms have been reported, including our present case.^[5-9] A summary of the cases is shown in Table 1. Patient ages ranged from 26 to 69 years (mean, 50 years). Two patients were male, and four were female. Four cases manifested as subarachnoid hemorrhage (SAH), and two were incidentally detected. The A1 segment on the agenesis side was absent or hypoplastic in all cases including ours. All patients had ACoA aneurysm. Six patients underwent aneurysm clipping. Two of the four patients presenting with SAH died, but good recovery was achieved in the other five patients.

Only 20 cases of Type D agenesis including ours have been reported.^[8,9] Based on the present findings, Type D agenesis is rare but may have a high incidence of ACoA aneurysm. Therefore, we suggest that patients with this type of anomaly should be followed up clinically and radiologically at close intervals not only to check for enlargement or deformation of the existing aneurysms but also to detect de novo aneurysms.^[8]

Conclusion

We presented a case of ICA agenesis with transcavernous anastomosis associated with ACoA aneurysms. We suggest that recognition of this anomaly has important implications in the surveillance and detection of associated aneurysms.

Financial support and sponsorship

Nil.

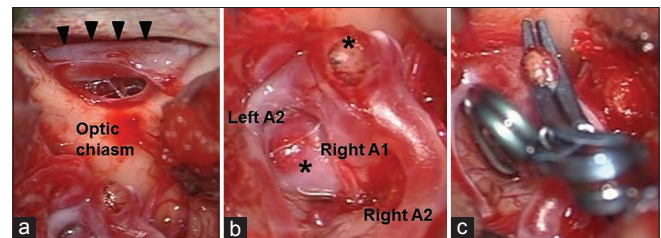


Figure 2: Intraoperative photographs before (a and b) and after clipping (c) Note that the transcavernous anastomosis (arrowheads) runs just below the optic nerves. Asterisks show anterior communicating artery aneurysms

Table 1: Summary of patients with Lie’s type D agenesis with intracranial aneurysms

Author	Age (year)	Sex	Symptom	Agenesis side	Aneurysm site	A1 on the agenesis side	Treatment	Outcome
Huber ^[5]	26	ND	SAH	Left	ACoA	-	Clipping	Dead
Tracy ^[6]	34	Male	Headache	Right	ACoA	-	Clipping	Good recovery
Quint <i>et al.</i> ^[7]	60	Female	SAH	Right	ACoA, ICA, MCA	-	None	Dead
Quint <i>et al.</i> ^[7]	65	Female	SAH	Left	ACoA	-	Clipping	Good recovery
Horie <i>et al.</i> ^[8]	55	Female	Incident	Left	ACoA	-	Clipping	Good recovery
Suyama <i>et al.</i> ^[9]	69	Female	SAH	Left	ACoA	-	Clipping	Good recovery
Present case (2014)	41	Male	Incident	Left	ACoA	-	Clipping	Good recovery

ACoA – Anterior communicating artery; ICA – Internal carotid artery; MCA – Middle cerebral artery; ND – Not described; SAH – Subarachnoid hemorrhage

Conflicts of interest

There are no conflicts of interest.

References

1. Smith KR Jr, Nelson JS, Dooley JM Jr. Bilateral “hypoplasia” of the internal carotid arteries. *Neurology* 1968;18:1149-56.
2. Meder JF, Blustajn J, Trystram D, Godon-Hardy S, Devaux B, Zuber M, *et al.* Radiologic anatomy of segmental agenesis of the internal carotid artery. *Surg Radiol Anat* 1997;19:385-94.
3. Padget DH. The development of the cranial arteries in the human embryo. *Contrib Embryol* 1948;212:207-61.
4. Lie TA. *Congenital Anomalies of the Carotid Arteries*. Amsterdam: Excerpta Medica; 1968. p. 44-9.
5. Huber G. Intracranial carotid anastomosis and partial aplasia of an internal carotid artery. *Neuroradiology* 1980;20:207-12.
6. Tracy PT. Unusual intercarotid anastomosis associated with anterior communicating artery aneurysm. Case report. *J Neurosurg* 1987;67:765-7.
7. Quint DJ, Boulos RS, Spera TD. Congenital absence of the cervical and petrous internal carotid artery with intercavernous anastomosis. *AJNR Am J Neuroradiol* 1989;10:435-9.
8. Horie N, Tsutsumi K, Kaminogo M, Morikawa M, Kitagawa N, Nagata I. Agenesis of the internal carotid artery with transcavernous anastomosis presenting with an anterior communicating artery aneurysm – A case report and review of the literature. *Clin Neurol Neurosurg* 2008;110:622-6.
9. Suyama K, Mizota S, Minagawa T, Hayashi K, Miyazaki H, Nagata I. A ruptured anterior communicating artery aneurysm associated with internal carotid artery agenesis and a middle cerebral artery anomaly. *J Clin Neurosci* 2009;16:585-6.
10. Afifi AK, Godersky JC, Menezes A, Smoker WR, Bell WE, Jacoby CG. Cerebral hemiatrophy, hypoplasia of internal carotid artery, and intracranial aneurysm. A rare association occurring in an infant. *Arch Neurol* 1987;44:232-5.