

Letter to the Editor

Embryology of the Ophthalmic Artery: a Revived Concept

M. KOMIYAMA

Department of Neurosurgery, Osaka City General Hospital; Osaka Japan

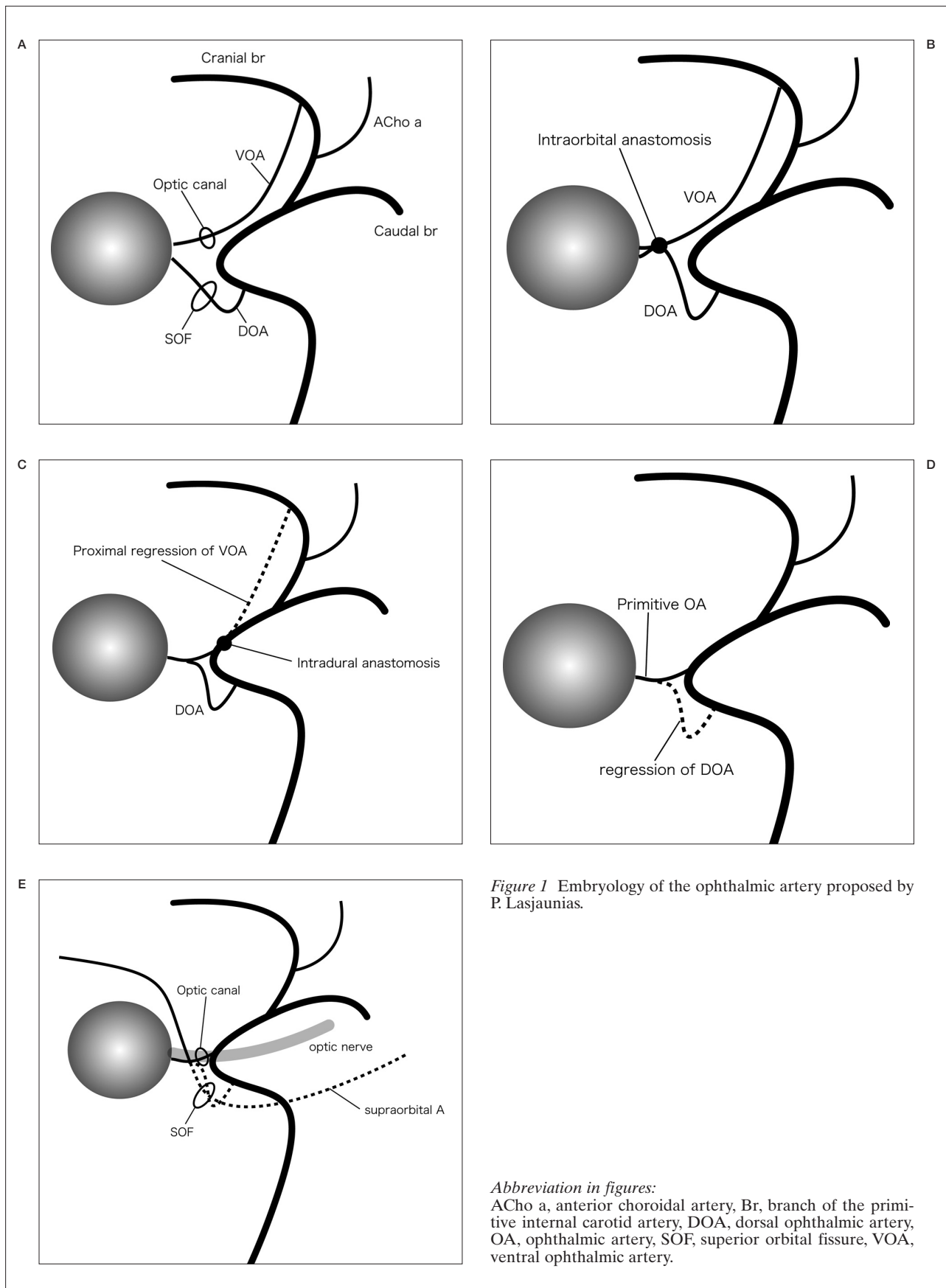
Key words: embryology, ophthalmic artery

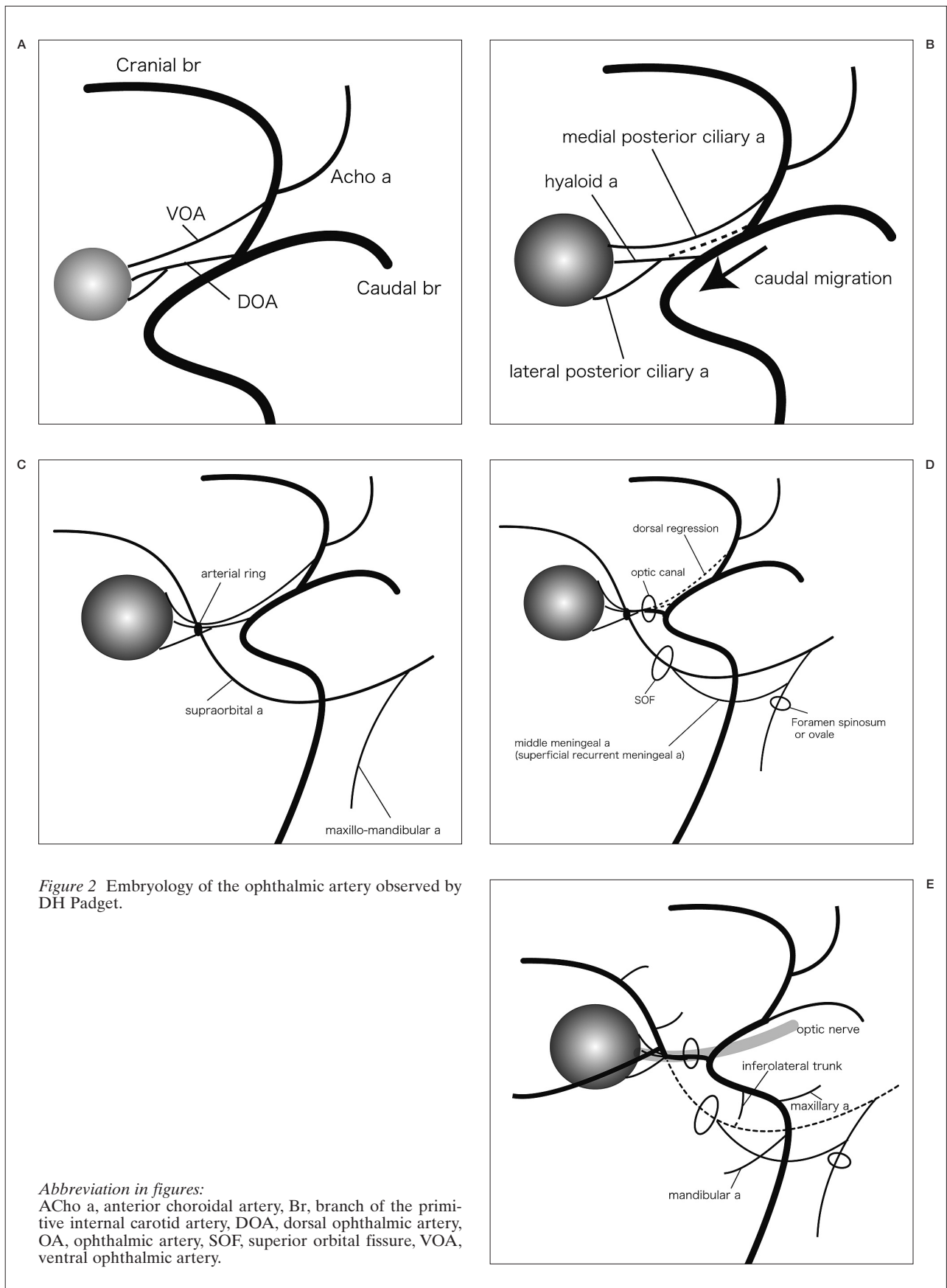
Embryology of the ophthalmic artery (OA) is complex, as elegantly depicted by Padget in detailed embryonic diagrams about 60 years ago¹. However, Lasjaunias et Al explained its processes differently with angiographic images² (Figure 1). According to their explanation, two primitive OAs supply the orbit first, i.e., the ventral OA (VOA) and dorsal OA (DOA) (Figure 1A). The VOA is the ocular artery, which originates from the anterior cerebral artery and passes through the optic canal while DOA originates from the internal carotid artery (ICA) at the carotid siphon runs through the superior orbital fissure (SOF). Then, two anastomoses are formed: one near the optic nerve in the orbit between the VOA and DOA (Figure 1B), and the other near the intradural optic canal between the VOA and the ICA (Figure 1C). The proximal parts of the VOA and DOA regress, resulting in the formation of the adult OA (Figure 1D). The remnant of the proximal DOA is the inferolateral trunk (inferior cavernous sinus artery). In the meanwhile, supraorbital artery (branch of the stapedial artery formed from the second aortic arch) also passes through the SOF and contributes to give off branches to the orbit, including ethmoid-nasal and lacrimal arteries (Figure 1E). This concept has been well accepted in the neuro-radiological field for more than 40 years³.

According to Padget¹ (Figure 2), however, the DOA first appears at the opposite side of the bifurcation of the primitive ICA, i.e., in

front of the caudal branch (future posterior communicating artery), giving off the hyaloid artery (future central retinal artery) and lateral posterior ciliary artery, which supply the dorso-lateral aspect of the developing optic vesicle (Figure 2A). The VOA appears at the primitive ICA near the origin of the anterior choroidal artery, and gives off the medial posterior ciliary artery, supplying the ventro-medial aspect of the optic vesicle. Subsequently, the origin of the DOA moves proximally after complex anastomotic processes called "caudal migration" to the point of the adult OA (Figure 2B). It never goes down to the cavernous sinus. The proximal portion of the VOA regresses and the adult OA is formed finally. At the same time, the stapedial artery gives off two branches: supraorbital and maxillo-mandibular artery (Figure 2C). The supraorbital artery enters the orbit through the SOF and anastomoses with the VOA-DOA complex, making a small arterial ring around the optic nerve, at the future second intra-orbital portion of the adult OA (Figure 2D). After regression of the ventral aspect of the arterial ring, the final adult configuration of the OA is established (Figure 2E).

As the arteries run together with the corresponding nerves in principle, the supraorbital artery accompanies the ophthalmic nerve (V1) and the maxillo-mandibular artery (future infra-orbital artery and inferior alveolar artery) accompanies the maxillary (V2) and mandibular nerves (V3), respectively. Thus, each artery





accompanies the division of the trigeminal nerves and passes through the corresponding fissure or foramina (SOF, foramina rotundum and ovale).

Embryologically, maxillary and mandibular nerves are related to the first aortic arch, but the ophthalmic nerve is different and not related to the first aortic arch. There is a possibility that the ophthalmic nerve is related to the pre-mandibular arch. In consideration of the branching order from the ICA of mandibular artery (vidian artery after exiting the skull base), maxillary artery (inferior hypophyseal artery), and the inferolateral trunk, and accompanying trigeminal nerves, the inferolateral trunk could be related to the dorsal remnant of the premandibular arch (Figure 2E).

In this communication, I would like to revise the widely accepted concept that only the VOA passes through the optic canal and contributes to vision, and the remnant of the DOA is inferolateral trunk. As Padget observed, I believe that the optic canal is for the ocular artery for vision consisting of both the VOA and DOA, and the SOF is for the orbital artery for

lacrimar secretion and orbital muscles consisting of the supraorbital artery of the stapedia artery. The DOA is more important for vision than the VOA since the DOA branches off the central artery of the retina.

References

- 1 Padget DH: The development of the cranial arteries in the human embryo. *Contrib Embryol* 32: 205-261, 1948.
- 2 Lasjaunias P, Moret J, Mink J: The anatomy of the inferolateral trunk (ILT) of the internal carotid artery. *Neuroradiology* 13: 215-220, 1977.
- 3 Lasjaunias P, Berenstein A: *Surgical Neuroangiography. Vol 3. Functional Vascular Anatomy in Brain, Spinal Cord and Spine.* Springer Verlag, Berlin, 15-87, 1992.

M. Komiyama
Department of Neurosurgery
Osaka City General Hospital
Osaka, Japan
1-13-22, Miyakojima-Hondori
Miyakojima, Osaka
Japan 534-0021
E-mail: komiyama@japan-mail.com

EDITORIAL COMMENT

Invited comment by Dr In Sup Choi

The author wrote a letter to editor concerning the embryology of the adult form of the ophthalmic artery. He suggests reversing the newer concept, established by Pierre Lasjaunias, in favor of the older one by Dorcas Hager Padget formulated in 1948.

Embryology itself is often quite controversial since it is not possible to observe the evolution of certain specifics continuously in human embryos. Knowledge of embryology is based on phylogenic studies and dissections.

Padget's report, published in 1948 gave us enormous information on the development of the vascular system of the central nervous system. It was based on the detailed observation of sectioned embryos of the Carnegie collection. Her ability as an illustrator and embryologist converted that information on sectioned specimens into critical knowledge of detailed arterial and venous development. However, it was based on her studies of embryology. Unfortunately, clinical correlation was not feasible in her time.

We know there are many embryonic variations “normal or abnormal” in all parts of the human body including the vascular system. These variations ought to be seen in clinical practice. For simple example, the trigeminal artery is the persistence of the embryonic connection between the internal carotid artery and basilar artery which is supposed to have regressed at seven to eight weeks of the embryonic stage. The development of the ophthalmic artery system is much more complex. Lasjaunias' explanation is based not only on the previous embryonic studies, but on clinical observation of such variations. There are many cases of arterial supply to the orbit originating exclusively from the cavernous segment of the internal carotid artery. These ophthalmic arteries enter the orbit through the superior orbital fissure instead of the optic canal. In some cases, the ophthalmic artery develops from the anterior cerebral artery, not from the paraclinoid segment of the internal carotid artery. Cases of two ophthalmic arteries, one from the anterior cerebral artery and one from the cavernous segment of the internal carotid artery have been reported.

All these variations can be explained by Lasjaunias' proposed theory while they cannot be explained if Padget's theory were correct.

Ms. Dorcas Hager Padget made tremendous contributions to human embryology but her observations on the development of the ophthalmic artery do not explain variations we see in clinical practice.

Invited comment Dr Philippe Mercier

The author has reviewed the Lasjaunias' chapter on “The embryonic arteries and the inferolateral trunk” and the desertation written by DH Padget in 1948 on the development of the cranial arteries in the human embryo. He drew diagrams and concluded that he believes the optic canal contains the supply for vision consisting of both the VOA and DOA, and the SOF contains the orbital artery towards the lacrimal gland and the orbital muscles consisting of the supraorbital artery of the stapedia artery. The DOA is more important for vision than the VOA since the DOA provides the central artery of the retina. The author also proposes that the inferolateral trunk (ILT) accompanying the trigeminal branches could be related to the dorsal remnant of the pre-mandibular arch.

In support of the PL concept, the development of the primitive ophthalmic artery depends on two arteries:

- the PVOA arising from the ACA and supplying a cerebral derivative (the eye)
- the PDOA arising from the horizontal carotid siphon at the junction of C6-C7.

Subsequently, two anastomoses are formed:

- inside the orbit, around the optic nerve between the PDOA and the PVOA
- intradurally, between the ICA and the PVOA.

The proximal part of the PDOA and PVOA regress to give rise to the POA entering the orbit by the optic canal. The remnant of the PDOA is the ILT supplying the V2 (F Rotundum), the VI (superior orbital fissure) and the roof of the cavernous sinus. Subsequently the stapedia system will provide the supply to the orbital muscles and the lacrimal

gland and this artery will anastomose with the POA with two possible dispositions: the meningo- meningeal variant fed by the middle meningeal artery and the lacrimal variant fed by the POA.

In support of the Padget theory, the PDOA appears first (stage 4-5 mm) and will supply the eyeball and lens. At stage 9mm, (embryo N° 163, plate 1) she describes a primitive ventral artery, in addition to the PDOA, supplying the plexus towards the eyeball and lens. The two arteries make a caudal migration, the proximal portion of the PVOA regresses and the OA adult is formed and subsequently the stapodial system connects to the OA.

After studying both authors, one may think they reached the same conclusion, the only difference being the name of the artery supplying the central retinal artery: for PL the PVOA, for Padget, the PDOA. The difference can be easily explained: in PL's classification, the vessel name refers to the fetal head position (that means that the PVOA is more ventral than the PDOA in the fetal situation) but in Padget's classification, in the rabbit, the name refers to the optic nerve's relationship (p. 242: the vessels (one penetrating the interior of the cup, the other vascularising its margin) belonging to the prominent dorsal ophthalmic branch of the carotid just described. Although the artery does appear to come from below in her illustrations (Mann 1928, cited by Padget) because of the angle at which the model of the eye is viewed, the carotid origin artery would be dorsal. Padget appears to have misinterpreted Mann's work and named that artery PDOA instead of PVOA. So, whatever the name, the ophthalmic artery gives off the central retina artery and enters the orbit by the optic canal.

With respect to the fact that the ILT could be the dorsal remnant of the premandibular arch, it is easy to see that if the premandibular arch supplied the VI entering the orbit by the supraorbital fissure, supplying the orbital muscles, nerves and lacrimal gland, it will not supply the eye and this can therefore not explain the cavernous origin of the ophthalmic artery, a well-known variant in clinical practice.

DOA dorsal ophthalmic artery - VOA ventral ophthalmic artery
 PDOA primitive dorsal ophthalmic artery - PVOA primitive ventral ophthalmic artery
 ILT inferior lateral trunk - OA ophthalmic artery