

# ***Endovascular Treatment of an Extracranial Internal Carotid Artery Aneurysm at the Skull Base with Mechanically Detachable Coils***

## **—Case Report—**

Masaki KOMIYAMA, Toshihiro YASUI, and Misao NISHIKAWA

*Department of Neurosurgery, Osaka City General Hospital, Osaka*

### **Abstract**

A 45-year-old male experienced a transient ischemic attack manifesting as left blurred vision and right hemiparesis. Angiography demonstrated an extracranial internal carotid artery aneurysm at the entrance of the carotid canal just above the C-1 vertebral arch. Intraluminal occlusion of the aneurysm was achieved with mechanically detachable coils under local anesthesia, and the carotid flow was preserved. There was no complication during or following the procedure. Treatment of aneurysms using detachable coils is an important alternative to surgical treatment when surgical access to the lesion is difficult.

**Key words:** endovascular treatment, internal carotid artery aneurysm, mechanically detachable coil, skull base lesion

### **Introduction**

Extracranial internal carotid artery aneurysms are rare,<sup>16)</sup> and are usually located at the common carotid bifurcation, where atherosclerosis most commonly occurs.<sup>13)</sup> The clinical manifestation is usually a mass effect on the surrounding structures, embolic or hemodynamic ischemia, or hemorrhage. Surgical obliteration of the aneurysm with preservation of carotid flow is the treatment of choice if the lesion is accessible.<sup>15,22)</sup> However, access for the surgical approach is more difficult for aneurysms with extremely distal locations at the skull base or of large sizes.<sup>1,2,5,18,23)</sup> Such inaccessible lesions are treated by occlusion of the internal carotid artery, by proximal ligation or trapping, using surgical or endovascular approaches. Both of these techniques carry inherent risks of cerebral infarction.<sup>3,6,7,10,13,20,21)</sup>

We describe a case of a distal internal carotid artery aneurysm at the skull base treated by intraluminal occlusion of the aneurysm using mechanically detachable coils.

### **Case Report**

A 45-year-old male experienced sudden onset of hoarseness which persisted for 1 month and then gradually disappeared. Four days after the onset of hoarseness, he noted left blurred vision during the night, which had subsided by the next morning. Eleven days later, he experienced loss of consciousness lasting for 5 minutes and mild right hemiparesis for 20 minutes. When he recovered from the right hemiparesis, he again noticed left blurred vision, which persisted for about 2 hours. On the same day, he was admitted to a local neurosurgical hospital. Computed tomography and magnetic resonance (MR) imaging demonstrated no intracranial abnormality. Cerebral angiography 4 days after admission disclosed an aneurysm of the left internal carotid artery at the entrance to the carotid canal just above the C-1 vertebral arch. Irregularity of the artery wall was demonstrated at the site of the aneurysm and in the parent artery near the aneurysmal neck (Fig. 1). This irregularity had disappeared on the follow-up angiogram 3 months later. Angiography revealed no obvious atherosclerotic changes either in the intracranial or extracranial vessels. He had been taking aspirin 80 mg and

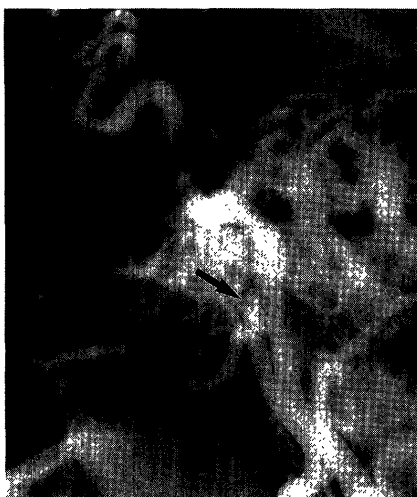


Fig. 1 Left common carotid angiogram (lateral view) 5 months prior to admission showing an aneurysm of the internal carotid artery at the skull base (*arrow*), and irregularity of the wall of the aneurysm and the nearby carotid artery.

ticlopidine 200 mg daily since the first admission. There was no subsequent recurrence of ischemia.

He was referred to us 5 months after the first ischemic episode. Both general physical and neurological examinations on admission were completely normal. His past history was unremarkable except for mild hypertension untreated for 30 years. He denied any history of trauma, surgery, or infection in the head and neck regions. Laboratory data were within normal limits. Intracranial neuroimaging examinations were normal. MR images of the craniovertebral junction disclosed the aneurysm near the atlas and the occipital condyle, but there was no thrombosis in the aneurysm or any other mass lesion.

We considered that this aneurysm required surgical or endovascular treatment to prevent future ischemic complications and possible mass effect. Due to the extremely distal location of the aneurysm at the skull base, we decided to use an endovascular technique.

Under local anesthesia, the left internal carotid artery was catheterized with a 6-French size diagnostic catheter through the transfemoral route. Angiography showed the aneurysm to be  $6 \times 6 \times 9$  mm, with neck width of 5 mm (Fig. 2). The tip of a Tracker-18 microcatheter with two platinum tip markers (Target Therapeutics, Fremont, Cal., U.S.A.) was bent to a curve using sterile hot water for stable positioning in the aneurysmal lumen. The tip of the microcatheter was easily navigated into the aneurysm through the diagnostic catheter. We used a

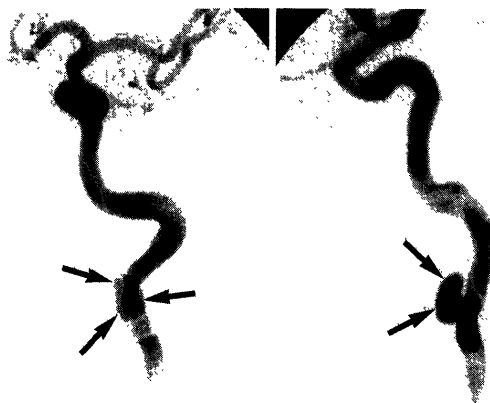


Fig. 2 Selective left internal carotid angiograms (*left*: anteroposterior view, *right*: lateral view) showing the aneurysm is  $6 \times 6 \times 9$  mm with neck width of 5 mm (*arrows*), but no apparent wall irregularity around the aneurysm.

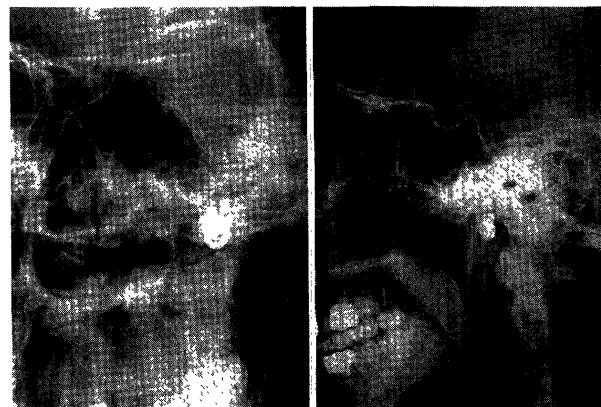

Fig. 3 Plain x-ray films (*left*: anteroposterior view, *right*: lateral view) showing two mechanically detachable coils deposited within the aneurysm. Total length of the coils is 40 cm.

mechanically detachable coil with an interlocking cylinder design (Target Therapeutics) that can be retrieved at any time before final detachment. A mechanically detachable coil with a diameter of 7 mm and total length of 20 cm ( $7 \text{ mm} \times 20 \text{ cm}$ ) was first introduced into the aneurysm and detached without difficulty. A second coil ( $6 \text{ mm} \times 20 \text{ cm}$ ) was introduced into the aneurysm in the same way, but insertion of the last 5 cm of the coil into the aneurysmal lumen took some time since this portion of the coil extruded into the lumen of the internal carotid artery (Fig. 3).

Post-embolization angiography showed subtotal occlusion ( $>90\%$ ) of the aneurysm, with partial opacification of the aneurysmal sac near the

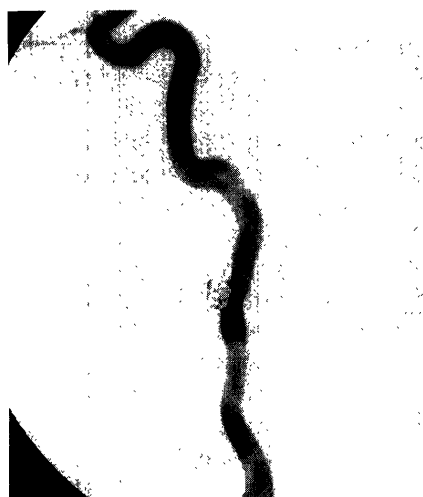

Fig. 4 Selective left internal carotid angiogram (lateral view) immediately after embolization showing partial opacification of the aneurysm near the aneurysmal neck.




Fig. 5 Follow-up selective left internal carotid angiogram (lateral view) 1 month after the embolization showing complete obliteration of the aneurysm (arrow).

aneurysmal neck (Fig. 4). He received systemic heparinization (24,000 international units/day) for 2 days, during which he underwent complete bed rest. Over the subsequent 2 weeks, he wore a neck collar to restrict neck movement. A daily dosage of 200 mg ticlopidine was given.

Follow-up angiography 1 month after the procedure showed complete obliteration of the aneurysm with preservation of patency in the left carotid artery (Fig. 5). Ticlopidine medication was discontinued 1 month after this angiography. Eight months following the procedure, he had experienced

no further ischemic episodes. A 1-year follow-up angiography is planned to check for any occlusive changes.

## Discussion

Advances in skull base surgery now allow approaches to extremely distal internal carotid artery lesions. However, access to a lesion located at the entrance of the carotid canal requires various special techniques. Procedures which may be needed include ligation of the external auditory canal and the Eustachian tube and removal of the petrosal bone, resulting in sacrifice of conduction hearing.<sup>8)</sup> The lower division of the facial nerve may require elevation with the parotid gland, when the muscular and ligamentous tissues of the mastoid, tympanic, and sphenoid bones are reflected inferiorly for access to the lesion.<sup>19,23)</sup> Several mandibular osteotomies and mandibular subluxation may be required for better surgical exposure.<sup>2,4,6)</sup> These procedures to expose the extremely distal carotid artery near the skull base are associated with high morbidity.

In contrast, endovascular treatment faces no such obstacles to reaching the aneurysm through the intraluminal route. In the present patient, the entire therapeutic procedure was completed under local anesthesia within 1 hour under full neurological monitoring. This could not be accomplished during open surgery under general anesthesia.

The initial angiography in our patient showed irregularity in the wall of the aneurysm and nearby in the internal carotid artery. This irregularity had disappeared by the follow-up angiography 3 months later. This irregularity might have been vasospasm, but we believe there was a relationship to the embolic source. An occlusion test of the internal carotid artery by direct pressure or by balloon catheter may dislodge emboli attached to the aneurysmal wall into the cerebral arterial tree.<sup>12)</sup> Likewise, endovascular treatment in the acute stage may be dangerous because introduction of the coils into the aneurysm can dislodge emboli. Should angiography disclose such wall irregularity, endovascular treatment should be delayed to allow control of the embolic source by medical treatment, unless emergency occlusion of the aneurysm is required.

Conventional coils have been used for occluding aneurysms, but there are risks in coil placement because these coils cannot be retrieved once partially ejected from the catheter or released into the aneurysm.<sup>11,14)</sup> Treatment of intracranial aneurysms with detachable coils was first reported in 1991.<sup>9)</sup> The detachment mechanisms now available are either elec-

trical<sup>9)</sup> or mechanical.<sup>17)</sup> Each design has advantages and disadvantages. We used mechanically detachable coils chiefly because electrically detachable coils are not currently available in Japan. The mechanically detachable coil design allows quick detachment and has significantly great separation strength while inside the catheter, making premature detachment unlikely.<sup>17)</sup> However, the interlocking cylinder joint in mechanically detachable coils may hook or displace the previously released coils. We believe that further design improvement is necessary. An electrically detachable coil will not displace any coils previously detached during release, but electrical detachment requires 4–12 minutes for electrolytic cleavage between the coil and the guidewire.<sup>9)</sup>

Endovascular treatment with detachable coils is an important alternative to surgical treatment for internal carotid artery aneurysms except when surgical obliteration of the aneurysm is absolutely indicated. However, long-term follow-up is required to validate this mode of therapy.

### References

- 1) Ausman JI, Pearce JE, de los Reyes RA, Schanz G: Treatment of a high extracranial carotid artery aneurysm with CCA-MCA bypass and carotid ligation. Case report. *J Neurosurg* 58: 421–424, 1983
- 2) Balagura S, Carter JB, Gossett DL: Surgical approach to the high subcranial internal carotid artery. *Neurosurgery* 16: 402–405, 1985
- 3) Braun IF, Battey PM, Fulenwider JT, Per-Lee JH: Transcatheter carotid occlusion: An alternative to the surgical treatment of cervical carotid aneurysms. *J Vasc Surg* 4: 299–302, 1986
- 4) Cantore GP, Delfini R, Mariottini A, Santoro A, Cascone P: Anterior displacement of the mandible for better exposure of the distal segment of the extracranial carotid artery. *Acta Neurochir (Wien)* 86: 56–60, 1987
- 5) de Jong KP, Zondervan PE, van Urk H, Woodson GE, Hurt J: Extracranial carotid artery aneurysms. *Eur J Vasc Surg* 3: 557–562, 1989
- 6) Dichtel WJ, Miller RH, Feliciano DV: Lateral mandibulotomy: A technique of exposure for penetrating injuries of the internal carotid artery at the base of the skull. *Laryngoscope* 94: 1140–1144, 1984
- 7) Ehrenfeld WK, Stoney RJ, Wylie EJ: Relation of carotid stump pressure to safety of carotid artery ligation. *Surgery* 93: 299–305, 1983
- 8) Fisch UP, Oldring DJ, Senning Å: Surgical therapy of internal carotid artery lesions of the skull base and temporal bone. *Otolaryngol Head Neck Surg* 88: 548–554, 1980
- 9) Guglielmi G, Viñuela F, Dion J, Duckwiler G: Electrothrombosis of saccular aneurysms via endovascular approach. Part 2: Preliminary clinical experience. *J Neurosurg* 75: 8–14, 1991
- 10) Haywood IR, Ellis H: Extra-cranial aneurysm of the internal carotid artery treated by proximal ligation. *Postgrad Med J* 55: 30–35, 1979
- 11) Higashida RT, Halbach VV, Dowd CF, Barnwell SL, Hieshima GB: Interventional neurovascular treatment of a giant intracranial aneurysm using platinum microcoils. *Surg Neurol* 35: 64–68, 1991
- 12) Ishikawa S, Sasaki U, Shima T, Kajikawa H, Miyazaki M: Extracranial aneurysm of the internal carotid artery at base of the skull. *No Shinkei Geka* 3: 337–342, 1975 (in Japanese)
- 13) Kaupp HA, Haid SP, Jurayj MN, Bergan JJ, Trippel OH: Aneurysms of the extracranial carotid artery. *Surgery* 72: 946–952, 1972
- 14) Lane B, Marks MP: Coil embolization of an acutely ruptured saccular aneurysm. *AJNR* 12: 1067–1069, 1991
- 15) Lasjaunias P, Berenstein A: *Surgical Neuroangiography, vol 2. Endovascular Treatment of Craniofacial Lesions*. New York, Springer-Verlag, 1987, pp 237–245
- 16) Margolis MT, Stein RL, Newton TH: Extracranial aneurysms of the internal carotid artery. *Neuroradiology* 4: 78–89, 1972
- 17) Marks MP, Chee H, Liddell RP, Steinberg GK, Panahian N, Lane B: A mechanically detachable coil for the treatment of aneurysms and occlusion of blood vessels. *AJNR* 15: 821–827, 1994
- 18) McCollum CH, Wheeler WG, Noon GP, DeBakey ME: Aneurysms of the extracranial carotid artery. Twenty-one years' experience. *Am J Surg* 137: 196–200, 1979
- 19) Mokri B, Piepgras DG, Sundt TM, Pearson B: Extracranial internal carotid artery aneurysms. *Mayo Clin Proc* 57: 310–321, 1982
- 20) Nordestaard AG, White GH, Cobb S, Mehringer M, Wilson SE: Blunt traumatic dissection of the internal carotid artery treated by balloon occlusion. *Ann Vasc Surg* 1: 610–615, 1987
- 21) Petrovic P, Avramov S, Pfau J, Fabri M, Obradovic J, Vukobratov V: Surgical management of extracranial carotid artery aneurysms. *Ann Vasc Surg* 5: 506–509, 1991
- 22) Raphael HA, Bernatz PE, Spittell JA, Ellis FH: Cervical carotid aneurysms: Treatment by excision and restoration of arterial continuity. *Am J Surg* 105: 771–778, 1963
- 23) Sundt TM Jr, Pearson BW, Piepgras DG, Houser OW, Mokri B: Surgical management of aneurysms of the distal extracranial internal carotid artery. *J Neurosurg* 64: 169–182, 1986

---

Address reprint requests to: M. Komiyama, M.D., Department of Neurosurgery, Osaka City General Hospital, 2-13-22 Miyakojima-hondohri, Miyakojima-ku, Osaka 534, Japan.

*Neurol Med Chir (Tokyo)* 35, October, 1995