

Computed Tomographic Evaluation of Bleeding Sites in Primary Pontine Hemorrhages

Masaki Komiyama, MD; Toshihiro Yasui, MD;
Hisatsugu Yagura, MD; and Yoshihiko Fu, MD

Background: With the aim of identifying common bleeding sites and probable parent vessels in "small" primary pontine hemorrhages, we reviewed computerized tomographic scans of 20 patients with hematomas <2.5 cm in diameter.

Summary of Report: We used scans depicting the upper and lower pons and plotted the centers of the hematomas, assuming them to be a probable source of bleeding. No predilection sites were found on the axial plane.

Conclusions: Both the paramedian and the long and short circumferential arteries were probable sources of hemorrhage in the present series. (*Stroke* 1991;22:1309-1311)

The advent of computed tomography (CT) has demonstrated "small" primary pontine hemorrhages with minimal neurologic deficits with increasing frequency compared to the pre-CT era.¹⁻⁸ Today, magnetic resonance imaging not only locates the clot better but may allow estimates of the time interval from the ictus, even in the subacute and chronic stages.⁹

Although the autopsy group shows most primary pontine hemorrhages to be located in the tegmentum³ or at the junction of the basal and tegmental pons,¹⁰ increasing recognition of "small" primary pontine hemorrhages suggests a wider distribution of bleeding sites within the pons.^{7,8,11-13} We reviewed the CT findings of 20 patients with hematomas <2.5 cm in diameter and here present our findings.

Subjects and Methods

Over the past 6 years, we admitted to our clinic 54 patients with CT-documented pontine hemorrhage. Fifty-one of these patients (34 men and 17 women, aged 40-82 years; average, 59.2 years) were diagnosed as having primary pontine hemorrhage, excluding other etiologies by their clinical analysis, magnetic resonance imaging, and cerebral angiography.

To evaluate the source of the bleed, we determined the center of the hematoma on the CT to be the bleeding site in each case. Because this assump-

tion would apply better to smaller lesions, the present study was focused mainly on hematomas <2.5 cm in diameter. According to hematoma size, 51 patients were divided into three groups. Group A consisted of hematomas <1.5 cm in diameter; group B, 1.5-2.5 cm; group C, >2.5 cm.

There were 11 patients in group A (seven men and four women, aged 51-67 years; average, 58.9 years); nine in group B (eight men and one woman, aged 43-67 years; average, 57.8 years); and 31 in group C (19 men and 12 women, aged 40-82 years; average, 61.0 years). All the patients in groups A and B were alive at the latest follow-up.

We also reviewed risk factors, such as hypertension and diabetes mellitus, in each group. None of the patients in these three groups was on anticoagulant therapy or had any bleeding disorder or systemic arteritis.

The CT images were 1.0 cm thick, and the centers of the hematomas were plotted on figures depicting the upper or lower pons in each group.

Results

Figures 1 and 2 show the estimated centers of the hematomas in each group. In group A, the centers of the hematomas tended to lie off the midline, predominantly in the tegmental region or at the junction of the basal and tegmental pons (Figure 1). In group B, they tended to lie in the midline, partially because of the larger size of the hematoma. In some cases in both groups, they were located within the basal pons (Figure 2).

These figures show that there are no specific bleeding sites on the axial plane. Although none of the

From the Department of Neurosurgery, Baba Memorial Hospital, Sakai, Osaka, Japan.

Address for reprints: Dr. Masaki Komiyama, MD, Department of Neurosurgery, Baba Memorial Hospital, 244, Higashi 4, Hamadera-Funao-Cho, Sakai, Osaka, 592 Japan.

Received February 14, 1991; accepted May 20, 1991.

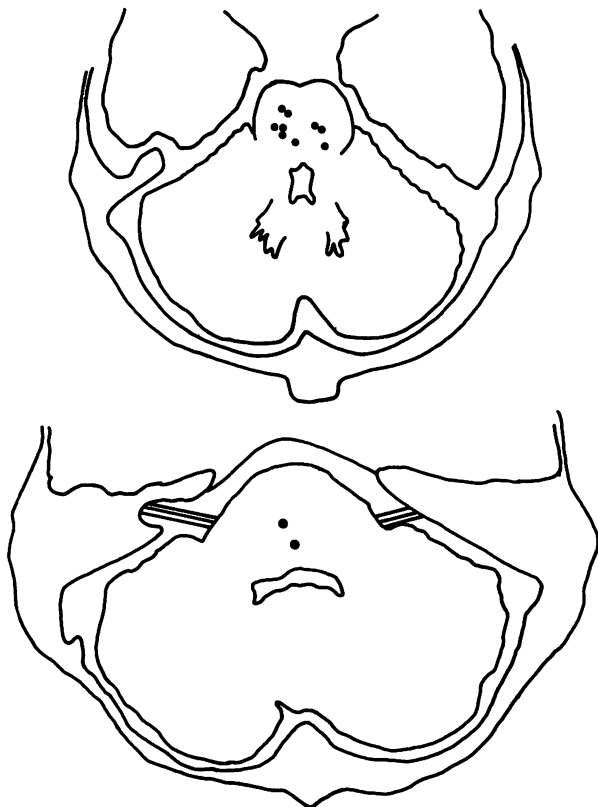


FIGURE 1. Upper (top panel) and lower (bottom panel) pons. The centers of pontine hemorrhages <1.5 cm are plotted. They tend to lie off the midline predominantly in the tegmental region or at the junction of the basal and tegmental pons.

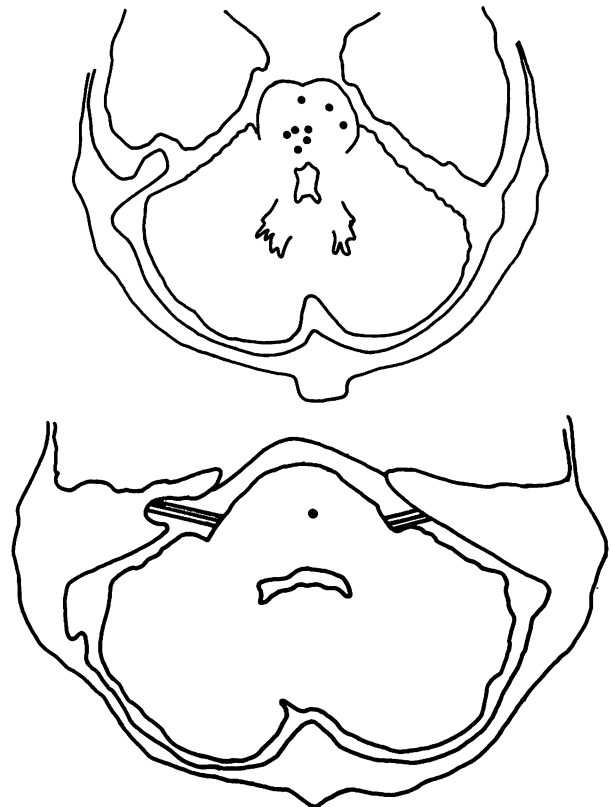


FIGURE 2. Upper (top panel) and lower (bottom panel) pons. The centers of pontine hemorrhages >1.5 cm and <2.5 cm are plotted. They tend to lie in the midline region. In two cases, they are located in the basal pons.

hematomas extended into the medulla oblongata, one in group A and two in group B involved the midbrain.

Hypertension was noted in 10 of 11 cases in group A, seven of nine cases in group B, and 22 of 31 cases in group C. Diabetes mellitus was found in two of 11 cases in group A, two of nine cases in group B, and none of 31 cases in group C. The four patients with diabetes mellitus also had hypertension. Thus, it is obvious that hypertension is a risk factor of primary pontine hemorrhage but that diabetes mellitus is not. There is no significant difference in the incidence of hypertension between groups A plus B and group C ($p>0.05$).

Figure 3 shows representative CT images with small hematomas (group A) located centrally and laterally.

Discussion

The paramedian arteries and the long and short circumferential arteries are the two major channels of blood supply to the pons. No large individual varieties occur in the normal arterial pattern in the pons.¹⁴ Although tegmentum mainly is supplied by the short and long circumferential arteries, it also gets blood through the paramedian arteries.¹⁴ Part of the lateral tegmentum is supplied by the long circumferential arteries, which are not present in the lower pons.¹²

Dinsdale⁴ reported that bleeding in all of 30 autopsied cases was found to occur near the junction of

the basal and tegmental pons and that the source of bleeding was the distal portion of the paramedian arteries arising from the basilar artery. Nakajima et al¹⁰ reported from autopsies of 24 fatal pontine hemorrhages that the hematoma was located mainly near the junction of the basal and tegmental pons. Extension of hematoma to the medulla oblongata is rare,^{3,4,10} as is true in our series. In recent years, however, lateral hematomas in the pons are well recognized by CT.^{7,8,11-13}

Various explanations, such as rupture of microaneurysms due to arterionecrosis and rupture of an arteriosclerotic vessel without any microaneurysm, have been offered to explain formation of hypertensive intracerebral hematomas. The actual mechanism cannot always be determined. Arterionecrosis, fibrinoid or hyalinoid degeneration, and lipohyalinosis are terms used to refer to the hypertensive changes in the perforating vessels.

Ishizaki¹⁵ reported that arterionecrosis is seen solely in the paramedian regions of the basal pons and not in the tegmentum and that the hemorrhages extended to the tegmentum secondarily. Microaneurysms are reported predominantly on the paramedian arteries originating from the basilar trunk.¹⁰ On the other hand, Fisher¹⁶ noted that in serial microscopic sections, there was no aneurysmal formation at the site of rupture, suggesting primary rupture of an artery 200 μ m in

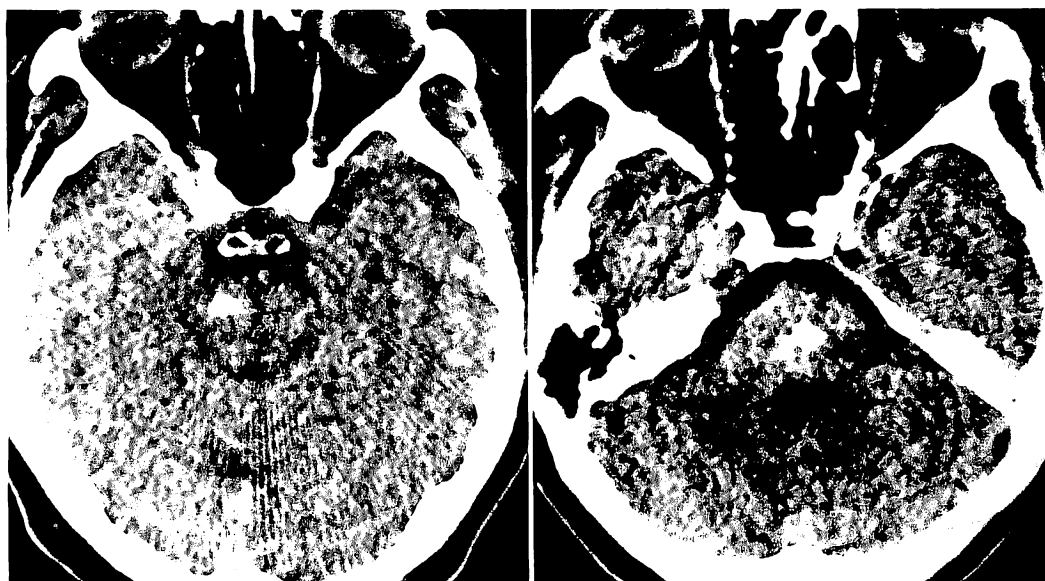


FIGURE 3. Computed tomographic images showing small hematomas located laterally (left panel) and at the very center of the pons (right panel).

diameter to be the cause of a fatal pontine hemorrhage. Kameyama¹⁷ observed that fibrinoid degeneration was found predominantly in an artery with a diameter of 50–100 μm in the basal pons. Dinsdale⁴ observed arteriosclerotic changes and hyaline degeneration, both of which may produce microaneurysms, predominantly at the junction of the basal and tegmental pons where the perforating vessels have their maximum number of branching. A lateral or a dorsolateral lesion can arise from limited hemorrhage of the circumferential arteries, whereas a central lesion can result from more extensive bleeding from the same vessel or from rupture of the paramedian arteries.¹³

In this series, there seems to be no specific site for pontine hemorrhage on the axial plane because the sites of bleeding are confined neither to the paramedian area nor to the junction of the basal and tegmental pons. Thus, in agreement with the report by Caplan and Goodwin,¹² our findings show that not only the paramedian arteries but also the circumferential arteries are the causative vessels for primary pontine hemorrhage.

It is obvious that hypertension is a significant risk factor for primary pontine hemorrhage, but there is no statistically significant difference in the incidence of hypertension between groups A plus B and group C. Thus, hypertension appears not to determine the hematoma size.

The wide variety of clinical presentations ranging from no neurologic deficit to a catastrophic fatality is explained by the variability in location and extension of the pontine hemorrhage. Further pathologic studies are necessary to pinpoint the responsible vessels in most primary pontine hemorrhages.

References

1. Epstein AW: Primary massive pontine hemorrhage: A clinicopathological study. *J Neuropathol Exp Neurol* 1951;10:426–448
2. Steegmann AT: Primary pontine hemorrhage: With particular reference to respiratory failure. *J Nerv Ment Dis* 1951;114:35–65
3. Watanabe R: Clinicopathological study on primary massive pontine hemorrhage. *Clin Neurol* 1963;3:94–112
4. Dinsdale HB: Spontaneous hemorrhage in the posterior fossa. *Arch Neurol* 1964;10:200–217
5. Payne HA, Maravilla KR, Levinstone A, Heuter J, Tindall RSA: Recovery from primary pontine hemorrhage. *Ann Neurol* 1978;4:557–558
6. Lavi E, Rothman S, Reches A: Primary pontine hemorrhage with complete recovery. *Arch Neurol* 1981;38:320
7. Del-Brutto OH, Noboa CA, Barinagarrementeria F: Lateral pontine hemorrhage: Reappraisal of benign cases. *Stroke* 1987;18:954–956
8. Komiyama M, Boo YE, Yagura H, Yasui T, Hakuba A, Nishimura S: A clinical analysis of 32 pontine brainstem haemorrhages; with special reference to surviving but severely disabled cases. *Acta Neurochir (Wien)* 1989;101:46–51
9. Komiyama M, Hakuba A, Inoue Y, Yasui T, Yagura H, Baba M, Nishimura S: MR imaging of brainstem hemorrhage. *AJNR* 1988;9:261–268
10. Nakajima K, Ito Z, Hen R, Suzuki A, Fukasawa H: Clinicopathological study of pontine hemorrhage: II. Pathological aspects. *Brain and Nerve* 1977;29:1157–1165
11. Kase CS, Maulsby GO, Mohr JP: Partial pontine hematomas. *Neurology* 1980;30:652–655
12. Caplan LR, Goodwin JA: Lateral tegmental brainstem hemorrhages. *Neurology* 1982;32:252–260
13. Kushner MJ, Bressman SB: The clinical manifestations of pontine hemorrhage. *Neurology* 1985;35:637–643
14. Hassler O: Arterial pattern of human brainstem: Normal appearance and deformation in expanding supratentorial conditions. *Neurology* 1967;17:368–375
15. Ishizaki T: Origin and extension of hypertensive pontine hemorrhage. *Clin Neurol* 1973;13:561–567
16. Fisher CM: Pathological observations in hypertensive cerebral hemorrhage. *J Neuropathol Exp Neurol* 1971;30:536–550
17. Kameyama M: Vascular lesions in cerebral apoplexy. *Clin Neurol* 1964;8:387–391

KEY WORDS • cerebral hemorrhage • tomography, x-ray computed • pons